

Evaluation of Women over 40 with Abnormal Uterine Bleeding

Dr. Urvashi Sinha, Dr. Jyothi Unni, Dr. Nina Mansukhani, Dr. Vandana Khanijo
Jehangir Hospital, Pune, India

Context: : About 33% of women present to the gynaecologist with Abnormal Uterine Bleeding (AUB), and this proportion rises to 69% in case of perimenopausal age group.¹ Evaluation aims at establishing a specific diagnosis in the least invasive manner.

Objective: To correlate symptomatology with Trans Vaginal Ultrasound (TVS), hysteroscopy and histopathological findings in women with Abnormal Uterine Bleeding

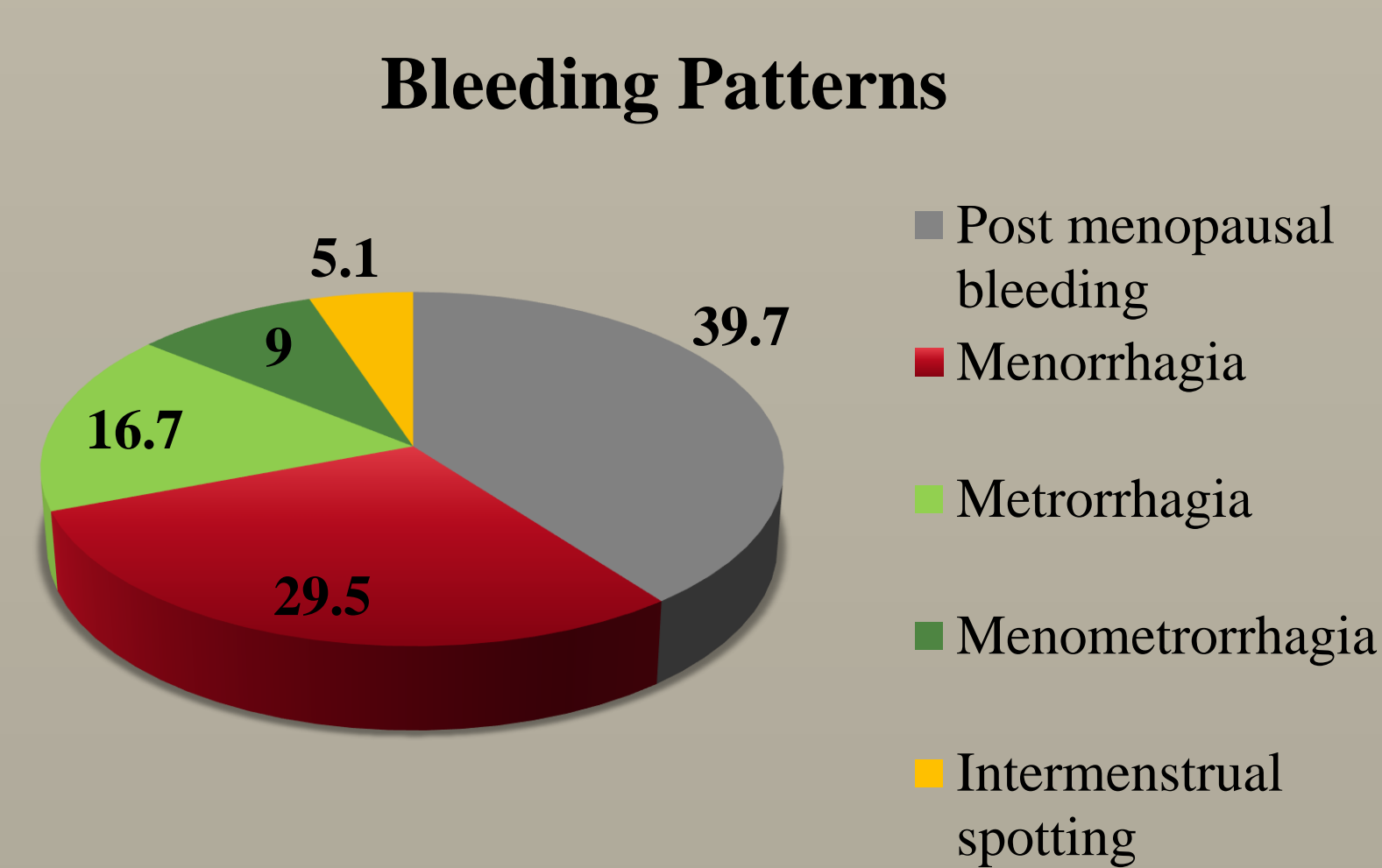
Material and Methods:

Women over 40 years, who presented to Jehangir Hospital, Pune, India with abnormal uterine bleeding between 01 January 2015 and 31 December 2015 were included. Women with bleeding disorders, known genital tract malignancy and those on anticoagulants were excluded.

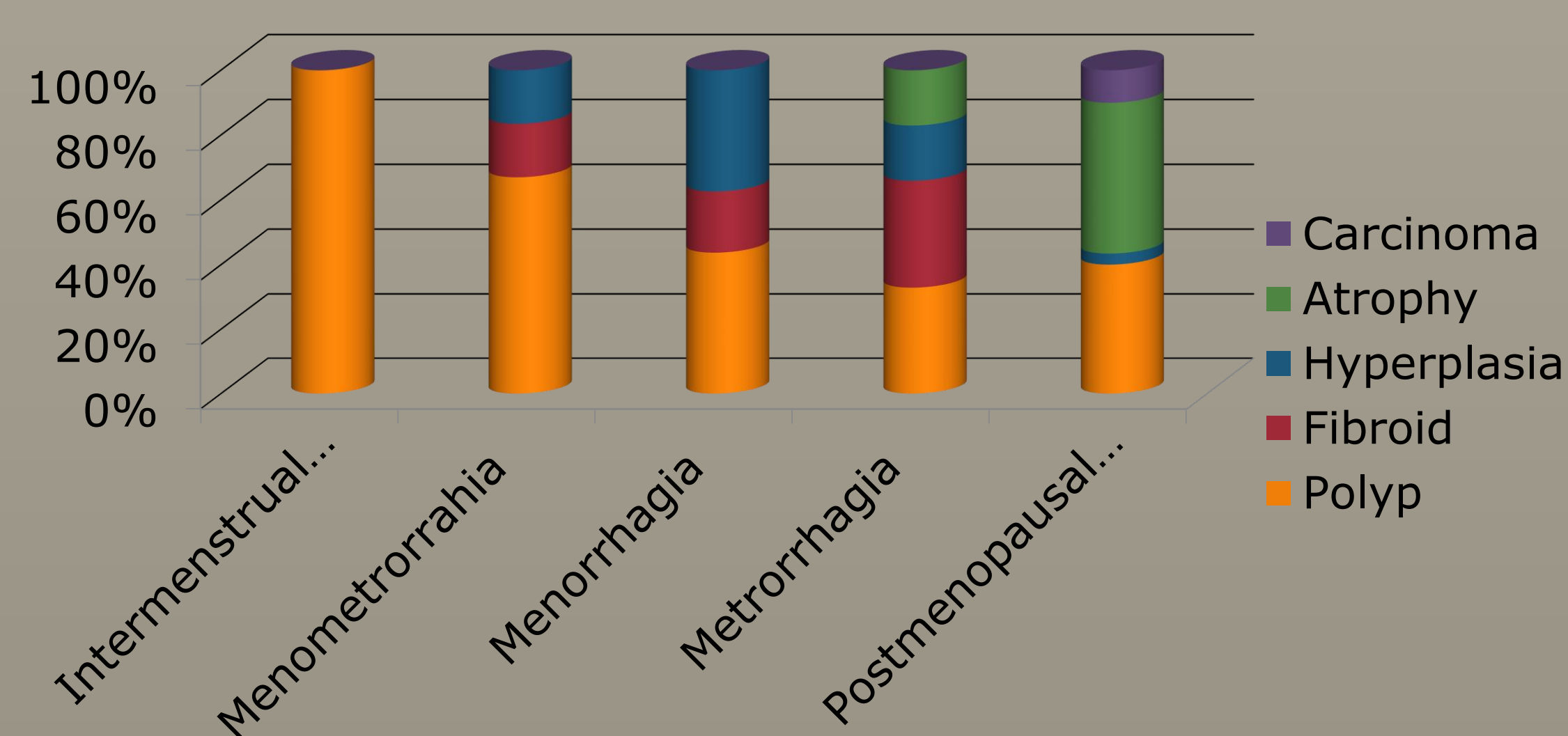
A detailed history was taken and a thorough clinical examination was done. A TVS and diagnostic hysteroscopy were performed. Endometrial samples were taken. Biopsies were taken from focal lesions. Endometrial polyps and sub mucous myomas were resected and sent for histopathology.

Results:

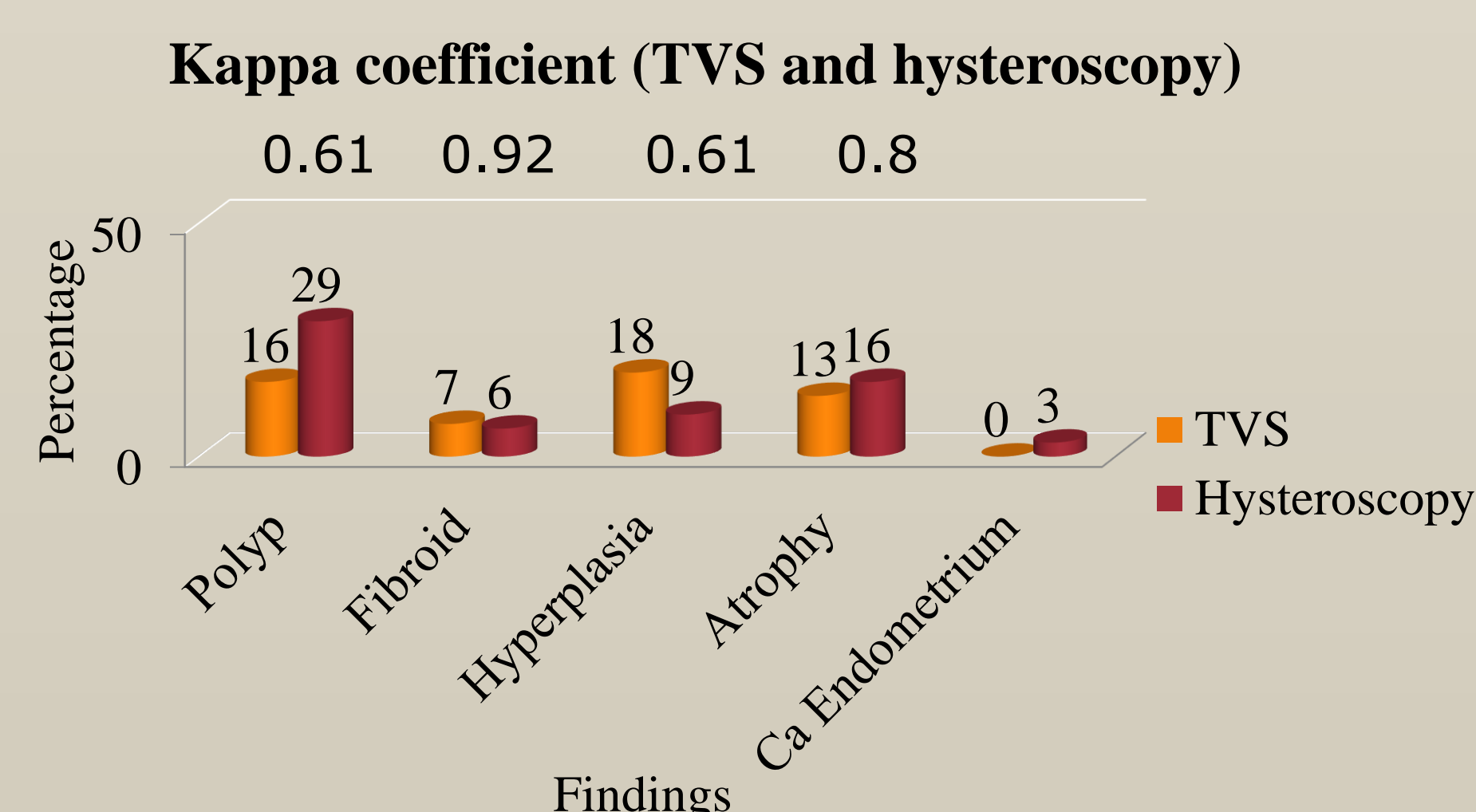
78 women were enrolled. The most common complaint (39.7%) was post menopausal bleeding (PMB). 29.5% of them had menorrhagia.



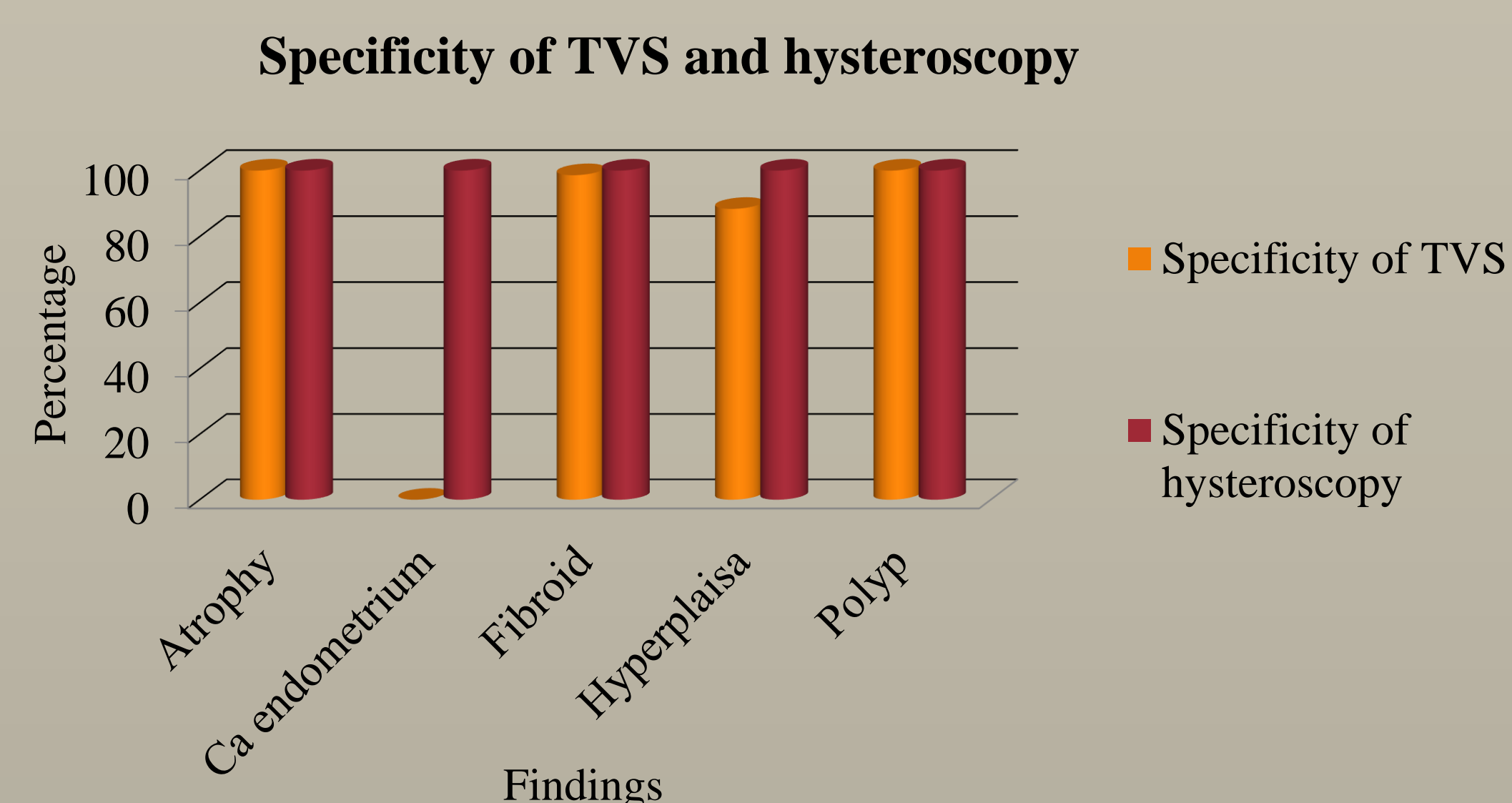
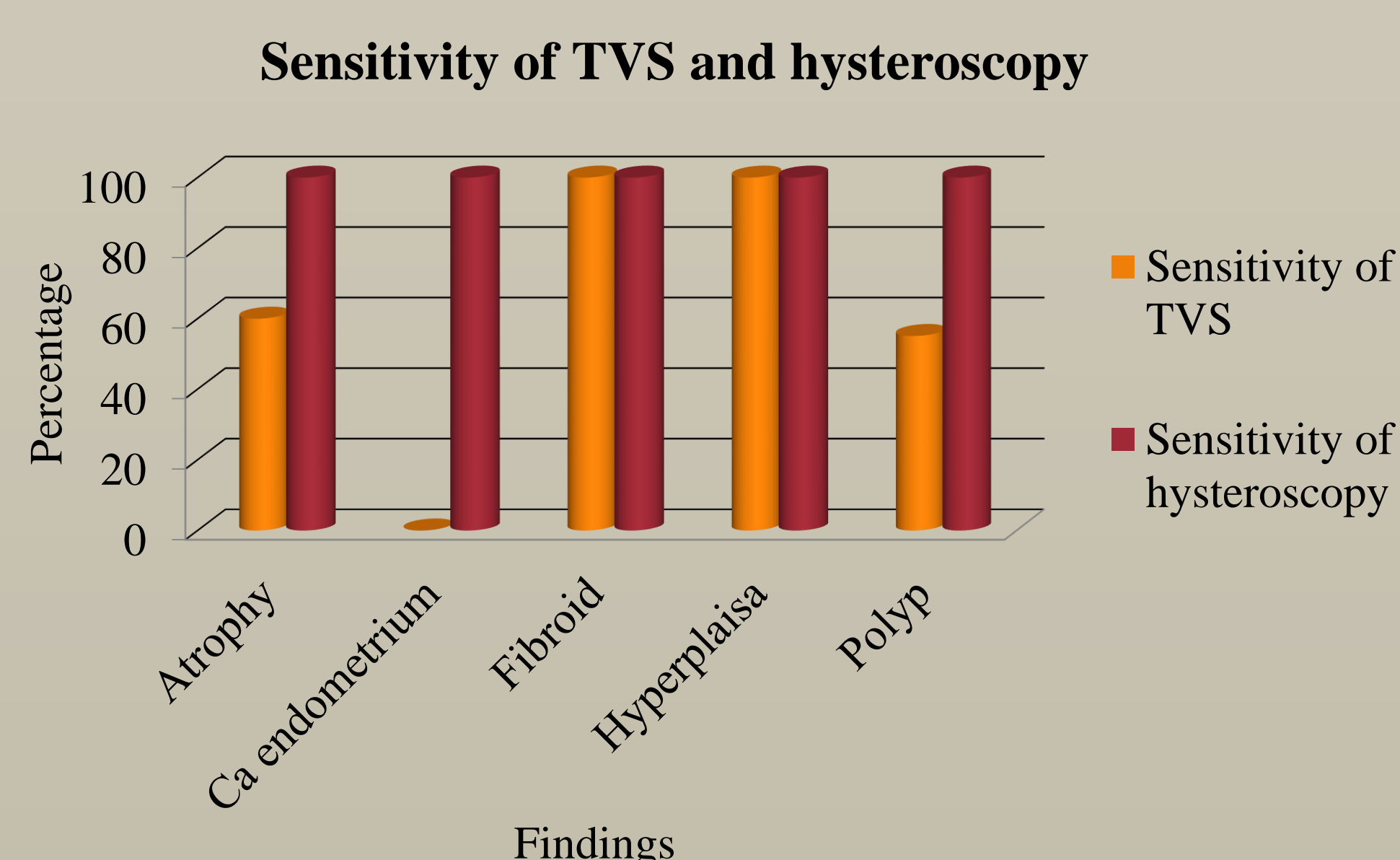
One third of women with PMB had atrophy. Endometrial polyps were the major cause of AUB. 36% of those with menorrhagia, 55% of women with metrorrhagia and 60% of those with menometrorrhagia had polyps.



Almost 50% of women with polyps were not reported to have an intra-cavitary lesion on TVS. Majority of post menopausal women with ET > 12 mm had a polyp and two women had Carcinoma endometrium.



Hysteroscopy had sensitivity, specificity, PPV and NPV of 100% for detection of all endometrial pathologies.



Discussion: Garuti G et al also found similar results confirming high sensitivity and specificity of hysteroscopy in diagnosing endometrial polyp.²

Conclusion: Hysteroscopy remains the gold standard as a significant number of women with AUB have endometrial polyps, which may be missed on TVS. ET more than 12mm in post menopausal women does not necessarily indicate a malignancy.

References:

- Razzaq A, Shukar-ud Din S, Soomro N. Role of diagnostic hysteroscopy in case of abnormal uterine bleeding. Pak J Surg 2011;27(4):309-315.
- Garuti G, Sambruni J, Colonnelli M, Luerti M. Accuracy of hysteroscopy in predicting histopathology of endometrium in 1500 women. J Am Assoc Gynecol Laprosc 2011;8(2):207-213.